


A CLINICAL UPDATE ON THE MANAGEMENT OF

Infected Arteriovenous Graft (AVG) Access

FOR THE HEMODIALYSIS PATIENT



National
Kidney
Foundation™

- › AVG Access: Demographics and Infection Risk
- › Risks and Clinical Consequences of AVG Infection
- › Prevention and Management of AVG Infection
- › Cryopreserved Allograft
- › Allograft Method vs. Graft Excision Method
- › Evidence-Based Benefits and Risks Related to Cryopreserved Allograft
- › Care After Cryopreserved Allograft Placement

AVG ACCESS: DEMOGRAPHICS AND INFECTION RISK

Approximately 19% of U.S. hemodialysis patients dialyze with AVGs—the second choice in the order of preference for hemodialysis.¹ The primary reasons for using AVGs include insufficient venous vasculature for an AV fistula (AVF), failed AVF, and AVF failure to mature.² In general, older patients have a high rate of AVF nonmaturation due to comorbidities such as peripheral vascular and cardiovascular diseases.³⁻⁵ As the proportion of elderly patients on hemodialysis increases, the use of AVGs may rise.³⁻⁵

The major AVG complication is thrombosis, but infection is also common, affecting 9% to 20% of grafts.⁶ Primary graft infections are usually due to bacteria. Detection of bacterial causes is difficult since there are usually no visible signs at the graft site, but occasionally an abscess or pustule may be present.

RISKS AND CLINICAL CONSEQUENCES OF AVG INFECTION

Non-AVF access is a prime risk factor for infection—the second leading cause of death in hemodialysis patients.^{7,8} The synthetic material of AVGs, commonly expanded polytetrafluoroethylene (ePTFE), is porous and therefore provides an opportune medium for the formation of biofilms, causing general infection. Biofilms make the resident microbes resistant to both natural and pharmacologic defenses.⁹ The incidence of AVG infection is from 9% (forearm) to 20% (thigh).⁶ While this is significantly lower than central venous catheter (CVC), it is ten times higher than AVF.^{10,11} Infection is a common cause of graft loss, accounting for 35% of patients losing AVGs.¹²

Risk of infection associated with AVGs includes insufficient anti-sepsis during surgical procedure, length of function, repetitive cannulation, venipuncture technique with risk of contamination or hematoma formation, and HIV infection.^{13,14} Other risk factors are history of multiple infections, number of surgical revisions, obesity, and thrombosed, abandoned AVGs.² Moreover, patients on dialysis have compromised immune function, and those with diabetes are more prone to infection and poor wound healing. Graft site also impacts infection risk. Access infection is more likely to occur in thigh grafts than in upper extremity grafts due to the potential for enteric organism contamination.⁶ For this reason, placement of AVGs in lower extremity sites is usually a last resort.¹⁵

Gram-positive organisms are the main cause of graft infections, with *Staphylococcus aureus* being the most common AVG-relat-

ed bacteria.¹⁰ Infections caused by *Staphylococcus aureus* are prone to more complications and worse outcomes than other infections. Consequences of AVG infection include prolonged catheter-dependence leading to morbidity, multiple vascular-access procedures, loss of access site, lengthy hospitalization, metastatic infection, and patient mortality.^{6,10} Sepsis with multi-organ failure and endocarditis are other serious complications.¹⁶ One month prior to AVG infection, many patients may have a lower serum albumin level (albumin <3.5 mg/dL)—a well-known mortality risk factor.¹⁰ Another consideration is occult infection of old nonfunctioning AVGs, which has been linked to erythropoietin-resistant anemia and chronic inflammation.¹⁷

AVG infection results in multiple vascular-access procedures and prolonged dependence on central venous catheter (CVC). Costs incurred are substantial, including hospital stay, use of operating rooms, radiology and other in-patient hospital resources. Strategies to decrease graft infection would have a positive impact on the morbidity and substantial costs associated with vascular access infections.¹⁰

PREVENTION AND MANAGEMENT OF AVG INFECTION

Infection prevention is critical for vascular access maintenance. Strict dialysis precautions and aseptic technique are important in preventing and minimizing access infection.¹⁵ The World Health Organization recommends washing hands as follows:¹⁸

My 5 Moments for Hand Hygiene

1. Before touching a patient
2. Before clean/aseptic procedures
3. After body fluid exposure risk
4. After touching a patient
5. After touching patient surroundings

AVG infection management is a balance between resolving the infection while preserving the vascular access as follows:

SUPERFICIAL INFECTION¹⁵

- › Treat initially with broad-spectrum antibiotic therapy to cover both gram-negative and gram-positive microorganisms.
- › Base subsequent antibiotic therapy upon culture results.
- › Incision and drainage may be beneficial.

EXTENSIVE INFECTION¹⁵

- › Treat with appropriate antibiotic therapy.
- › Resection of the infected graft material.

Total removal of infected AVGs and placement of a new access device at a remote site may be required. This involves placement of a temporary dialysis catheter until the infection is resolved and results in losing the original graft site. Because potential access sites are limited, partial graft excision to salvage a site is also an acceptable method for treating graft infection.¹²

Lastly, patients with forearm AVG removed may have adequate upper arm veins for an AVF, or another ePTFE graft could be inserted at a different location. A tri-layer silicone sandwich ePTFE graft may also be a consideration, since the time to cannulation can be as short as 24-hours post operatively.

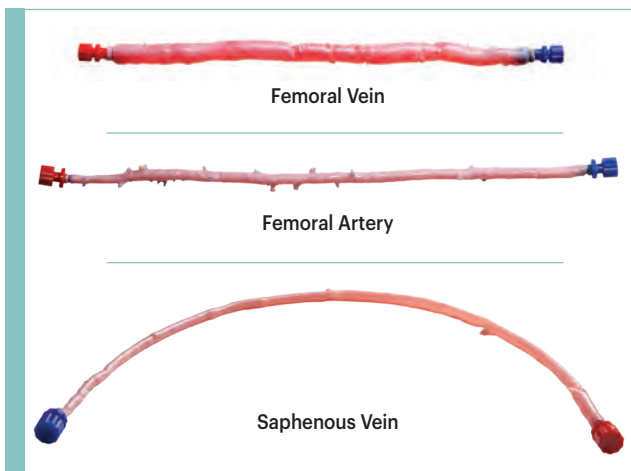
This resource focuses on cryopreserved allograft as an alternative for managing AVG infection in select hemodialysis patients with AVG access.

CRYOPRESERVED ALLOGRAFT

Cryopreserved allografts are cryogenically preserved cadaver vessels. (Figure 1)

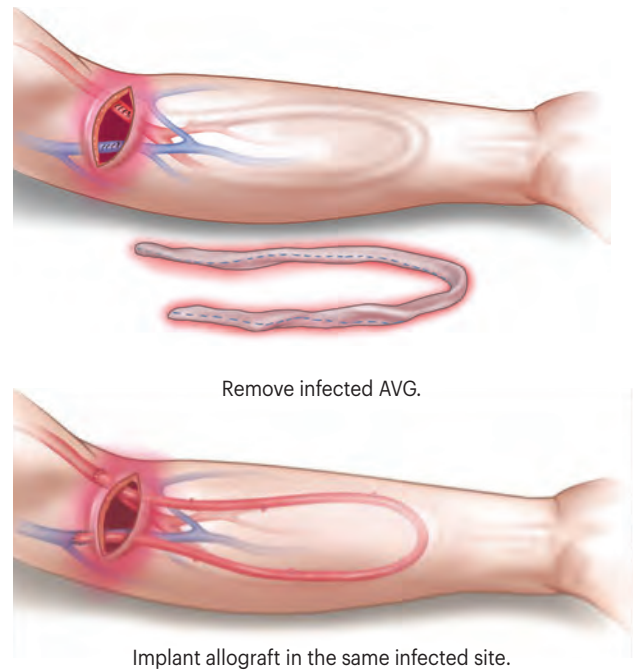
Cryopreserved allograft is an option for treating infected hemodialysis AVGs. Allografts have been implanted either adjacent to or directly into the infected fields using the same anastomotic regions, thus saving other sites for future access.

FIGURE 1. Cryopreserved Arteries and Veins



Used with permission of CryoLife, Inc.

FIGURE 2. Example of Allograft Method¹⁹



Used with permission of CryoLife, Inc.

ALLOGRAFT METHOD VS. GRAFT EXCISION METHOD

There are 2 methods for treating infected hemodialysis AVGs—the allograft method and the graft excision method. The graft excision method is generally used to manage a synthetic graft infection.

- › The allograft method is a single procedure which involves removing the infected AVG and implanting the cryopreserved allograft in the same infected site. Preserving the vascular access saves potential future AV access sites.¹⁹ Access is possible 10 to 14 days after implantation.^{20, 21} (Figure 2)
- › The graft excision method involves two separate procedures. First the infected AVG is removed. After the infection has cleared, a new AVG is placed in a different location, which diminishes potential sites for future access.¹⁹

A temporary CVC and IV antibiotic therapy are needed for both methods. The duration of the CVC is generally longer for the graft excision method because a CVC is needed after the first and second procedures, until the new AVG is ready for cannulation.¹⁹⁻²¹

EVIDENCE-BASED BENEFITS AND RISKS RELATED TO CRYOPRESERVED ALLOGRAFT

Lin et al. reviewed the use of cryopreserved allografts as an alternative dialysis access to treat AVG graft infection. Forty-five cryopreserved allografts were placed in 38 patients; infection was present in 36 patients. There was no recurrent infection in those treated for infection and 2 cases of aneurysmal degeneration near the puncture access site 12 and 14 months after the allografts were implanted respectively. The researchers reported that since the risk of recurrent infection was low, cryopreserved vein allograft is an acceptable graft conduit in treating prosthetic AVG infection.¹⁹ (Table 1)

In a prospective study, Matsuura et al. evaluated the use of cryopreserved femoral vein for angioaccess when prosthetic AVG could not be placed either due to infection or the loss of access sites. Of the 48 cryopreserved femoral veins placed in 44 patients, 38 were placed for infection. There were no cryopreserved femoral vein AVG infections over 1 year. The authors concluded that because of the relative resistance to infection, the cryopreserved allograft is useful in managing sites of AVG infection that might otherwise be lost to future angioaccess.²⁰ (Table 1)

In another study by Matsuura and colleagues, 43 cryopreserved allografts were placed in 43 patients with prosthetic AVG infections. Thirty-two of the cryopreserved allografts were constructed

adjacent to the infected AVG and 11 were placed into the infected field. There was one recurrent fungal infection (2.3%) over the mean follow-up of 418 days. This study showed that cryopreserved femoral vein, which seems to heal well in the setting of Gram-positive infections, proved useful in the treatment of infected AVGs while salvaging an angioaccess site that would otherwise be abandoned.²¹ (Table 1) A similar multi-center study was conducted using 52 allografts to treat AVG infection. The re-infection rate, calculated as bacteremia rates per 1,000 patient days, was 0.0062 (3.0%) over 2 years.²² (Table 1)

Finally, a single vascular surgery service used cryopreserved femoral grafts in 20 patients who were thought to be at high risk for AVG infection based on the presence of active infection (n = 4), thigh grafts (n = 14), or history of multiple access infections (n = 4), with two patients having two risk factors for subsequent access infection (thigh position and active infection). The 20 patients received cryopreserved allografts as follows: 14 thigh, 3 upper extremity, and 3 chest wall. Eleven patients (55%) had graft infection develop over the mean follow-up of 13 months. Since the majority of the infections were found in the thigh grafts (9/14), this study suggests that the routine use of the cryopreserved femoral vein graft in the thigh position should be avoided. The authors concluded that the use of cryopreserved femoral vein graft for in situ replacement of infected AVG should be considered if alternative sites for new AV access placement are not available.²³ (Table 1)

**TABLE 1:
ALLOGRAFTS FOR TREATING AVG INFECTIONS:
RE-INFECTION RATES**

Cryopreserved Femoral Vein	Patients Treated for AVG Infection	Re-Infection Rates	Follow-Up Period
Lin et al. ¹⁹	36	0%	1 Year
Matsuura et al. ²⁰	38	0%	1 Year
Matsuura et al. ²¹	43	2.3%	2 Years
Multicenter Data ²²	52	3%	2 Years
Bolton et al. ²³	4	NA*	13 months

*Re-infection rate of patients treated for active AVG infection is not available. Data reported is based on location of allograft placement only.

A disadvantage of cryopreserved grafts is that they can “sensitize” a patient. Transplantation of any allograft tissue can induce an anti-HLA antibody response in the recipient. The possibility that a patient may develop antibodies after allograft tissue transplantation should be considered for any patient who might be a future recipient of allograft tissue, organs, or cells. *Therefore, cryopreserved allografts should not be used for hemodialysis access in potential kidney transplant recipients.*²⁴

Other advantages and disadvantages of cryopreserved grafts to consider include patency, complications, and cost. Studies show that compared to PTFE grafts, cryopreserved grafts have similar patency, are more resistant to infection, but significantly more susceptible to aneurysms. The researchers concluded that cryopreserved allografts should be monitored aggressively for the development of aneurysms.²⁵ Regarding cost, the initial cryopreserved graft cost is considerably more expensive than PTFE grafts.²⁵ Graft performance, average hospital stay, and overall hospital cost should be considered to determine if the cryopreserved graft using the allograft method may be a cost-effective means of treating infected AVGs.

CARE AFTER CRYOPRESERVED ALLOGRAFT PLACEMENT

Cannulation of cryopreserved allografts is possible 10-14 days after placement, and when swelling has subsided so that the course of the AVG can be palpated.^{15, 21} Aseptic technique during cannulation, including standard precautions for hand washing and glove changes, is recommended to minimize risk of access infection. Cannulation techniques should be a hybrid of the techniques for a PTFE AVG regarding depth of the access and the texture of an autogenous vein. It is also necessary to rotate cannulation sites in order to avoid pseudoaneurysm formation.¹⁵ A retrospective study using constant cannulation (buttonhole technique) with cryopreserved femoral veins showed good outcomes related to patency and minimal infection risk.²⁶

A qualified individual should perform a physical examination to detect AVG dysfunction at least monthly. The 3 preferred surveillance techniques for stenosis of AVGs are: 1) intra-access flow using sequential measurements with time analysis; 2) directly measured or derived static venous dialysis; or 3) duplex ultrasound. Other acceptable techniques include physical findings of persistent swelling of the arm, presence of collateral veins, prolonged bleeding after needle withdrawal, or altered characteristics of pulse or thrill in the AVG. Unstandardized dynamic venous pressures should not be used.¹⁵

THE ALLOGRAFT METHOD PRESERVES THE VASCULAR ACCESS AND SAVES POTENTIAL FUTURE AV SITES.

DISCLAIMER

Information contained in this National Kidney Foundation educational resource is based upon current data available at the time of publication. Information is intended to help clinicians become aware of new scientific findings and developments. This resource is not intended to define a standard of care and should not be construed as one. Neither should the information be interpreted as prescribing an exclusive course of management.

Variations in practice will inevitably and appropriately occur when clinicians take into account the needs of individual patients, available resources, and limitations unique to an institution or type of practice. Every healthcare professional making use of information in this resource is responsible for interpreting the data as it pertains to clinical decision making in each individual patient.

Made possible through an educational grant from:



REFERENCES

1. Fistula First Data. Prevalent counts and rate. *Fistula First*. Available at: <http://fistulafirst.org/AboutFistulaFirst/FFBIData.aspx>. Accessed 31 July 2013.
2. Akoh JA. Prosthetic arteriovenous grafts for hemodialysis. *J Vasc Access*. 2009;10:137-147.
3. Lee HW, Allon M. When should a patient receive an arteriovenous graft rather than a fistula? *Semin Dial*. 2013;26:6-10.
4. O'Hare AM. Vascular access for hemodialysis in older adults: a "patient first" approach. *J Am Soc Nephrol*. 2013;24:1187-1190.
5. DeSilva RN, Patibandla BK, Vin Y, et al. Fistula first is not always the best strategy for the elderly. *J Am Soc Nephrol*. 2013;24:1297-1304.
6. Harish A, Allon M. Arteriovenous graft infection: a comparison of thigh and upper extremity grafts. *Clin J Am Soc Nephrol*. 2011;6:1739-1743.
7. Gulati S, Sahu KM, Avula S, et al. Role of vascular access as a risk factor for infections in hemodialysis. *Ren Fail*. 2003;25:967-973.
8. U.S. Renal Data System. *USRDS 2012 Annual Data Report: Atlas of Chronic Kidney Disease and End-Stage Renal Disease in the United States*. National Institutes of Health, National Institute of Diabetes and Digestive and Kidney Diseases; Bethesda, MD; 2012.
9. Vas SI. Infections related to prosthetic materials in patients on chronic dialysis. *Minerva Urol Nefrol*. 2004;56:259-264.
10. Minga TE, Flanagan KH, Allon M. Clinical consequences of infected arteriovenous grafts in hemodialysis patients. *Am J Kidney Dis*. 2001;38:975-978.
11. Schild AF, Perez E, Gillaspie E, et al. Arteriovenous fistulae vs. arteriovenous grafts: a retrospective review of 1,700 consecutive vascular access cases. *J Vasc Access*. 2008;9:231-235.
12. Schutte WP, Helmer SD, Salazar L, Smith JL. Surgical treatment of infected prosthetic dialysis arteriovenous grafts: total versus partial graft excision. *Am J Surg*. 2007;193:385-388.
13. Bachleda P, Utikal P, Kalinova L, et al. Infectious complications of arteriovenous ePTFE grafts for hemodialysis. *Biomed Pap Med Fac Univ Palacky Olomouc Czech Repub*. 2010;154:13-19.
14. Lafrance JP, Rahme E, Leloir J, Iqbal S. Vascular access-related infections: definitions, incidence rates, and risk factors. *Am J Kidney Dis*. 2008;52:982-993.
15. National Kidney Foundation KDOQI Work Group. KDOQI clinical practice guidelines and clinical practice recommendations for vascular access. *Am J Kidney Dis*. 2006;48:S176-S322.
16. Sexton DJ. Vascular access infections in patients undergoing dialysis with special emphasis on the role and treatment of *Staphylococcus aureus*. *Infect Dis Clin North Am*. 2001;15:731-742.
17. Nassar GM, Fishbane S, Ayus JC. Occult infection of old nonfunctioning arteriovenous grafts: a novel cause of erythropoietin resistance and chronic inflammation in hemodialysis patients. *Kidney Int Suppl*. 2002;(80):49-54.
18. World Health Organization. *Clean Care is Safer Care*. About SAVE LIVES: Clean Your Hands. Available at: <http://www.who.int/gpsc/5may/tools/en/>. Accessed on 13 Nov 2013.
19. Lin PH, Brinkman WT, Terramani TT, Lumsden AB. Management of infected hemodialysis access grafts using cryopreserved human vein allografts. *Am J Surg*. 2002;184:31-36.
20. Matsuura JH, Johansen KH, Rosenthal D, et al. Cryopreserved femoral vein grafts for difficult hemodialysis access. *Ann Vasc Surg*. 2000;14:50-55.
21. Matsuura JH, Rosenthal D, Wellons ED, et al. Hemodialysis graft infections treated with cryopreserved femoral vein. *Cardiovasc Surg*. 2002;10:561-565.
22. Multicenter data on file at CryoLife, Inc. (ML0101).
23. Bolton WD, Cull DL, Taylor SM, et al. The use of cryopreserved femoral vein grafts for hemodialysis access in patients at high risk for infection: a word of caution. *J Vasc Surg*. 2002;36:464-468.
24. Benedetto B, Lipkowitz G, Madden R, et al. Use of cryopreserved cadaveric vein allograft for hemodialysis access precludes kidney transplantation because of allosensitization. *J Vasc Surg*. 2001;34:139-142.
25. Madden RL, Lipkowitz GS, Browne BJ, Kurbanov A. Experience with cryopreserved cadaveric femoral vein allografts used for hemodialysis access. *Ann Vasc Surg*. 2004;18:453-458.
26. Gallichio MH, Chandolias N, Claudeanos K, et al. Successful utilization of cryopreserved human femoral vein or bovine carotid artery in the establishment of "button-holes" for hemodialysis. Abstract presented at: Vascular Access Society of America XIII Symposium; Orlando, FL, May 9-11, 2012.